

# Induction of atopic dermatitis (AD)-like symptoms in NC/Nga mutant mice with repeated topical applications of the hapten, oxazolone

Harun Rashid<sup>1</sup>, Agathe Bedard<sup>1</sup>, Alan Young<sup>1</sup>, Rana Samadfam<sup>1</sup>, Shi Yun Yeo<sup>3</sup>, Tanya Low<sup>3</sup>, Adrian Chong Nyi Sim<sup>3</sup>, Jie Zhang-Hoover<sup>2</sup>, Brian Henry<sup>3</sup> and Aaron Zefrin Fernandis<sup>3</sup>

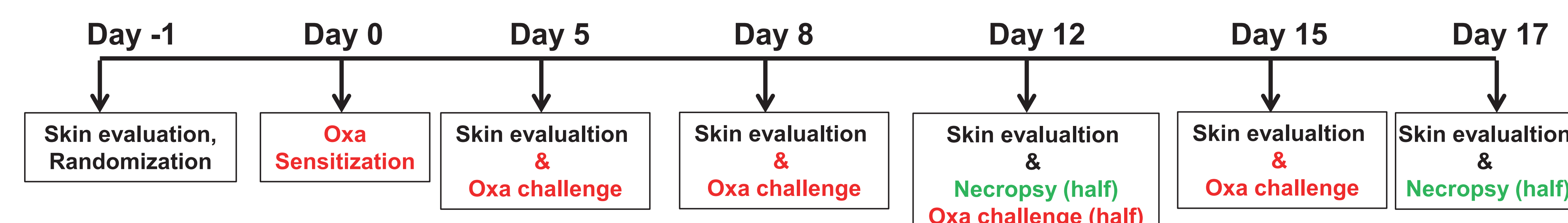
1. Charles River Laboratories, 2. Pharmacology (Boston), MSD, 3. Translational Medicine Research Centre, Singapore, MSD

## 1 Introduction

Among the different atopic dermatitis (AD) models in laboratory animals, those induced by epicutaneous application of allergens and haptens are more common due to their controlled induction. In this study, we examined induction of AD-like symptoms in NC/Nga mutant mice with repeated applications of the hapten, oxazolone.

## 2 Methods

Intended skin area was shaved and baseline skin thickness and redness were measured before start of the first sensitizing or priming application of oxazolone. Animals were sensitized on Day 0 by application of 0.3% oxazolone on the shaved skin area. On Days 5, 8, 12, and 15, challenges on the same skin site were performed by application of 0.3% oxazolone solution. Control animals received sensitization and challenge with the vehicle 80% acetone and 20% olive oil. Skin thickness, redness and scaling were scored on each challenge days. The first cohorts of mice were sacrificed on Day 12 following two challenges and the second cohorts were sacrificed on Day 17 following four challenges. Treated back skin sections were collected at necropsy for histopathological evaluation and in-situ zymography. Effects of standard of care (SOC) test agents were also examined on Oxazolone-induced AD-like symptoms in the mice. Effects of clobetasol cream (once daily topical application) and dexamethasone (once daily oral gavage) was assessed in prophylactic and therapeutic dosing protocols.



## 3 Results: In-life clinical scores

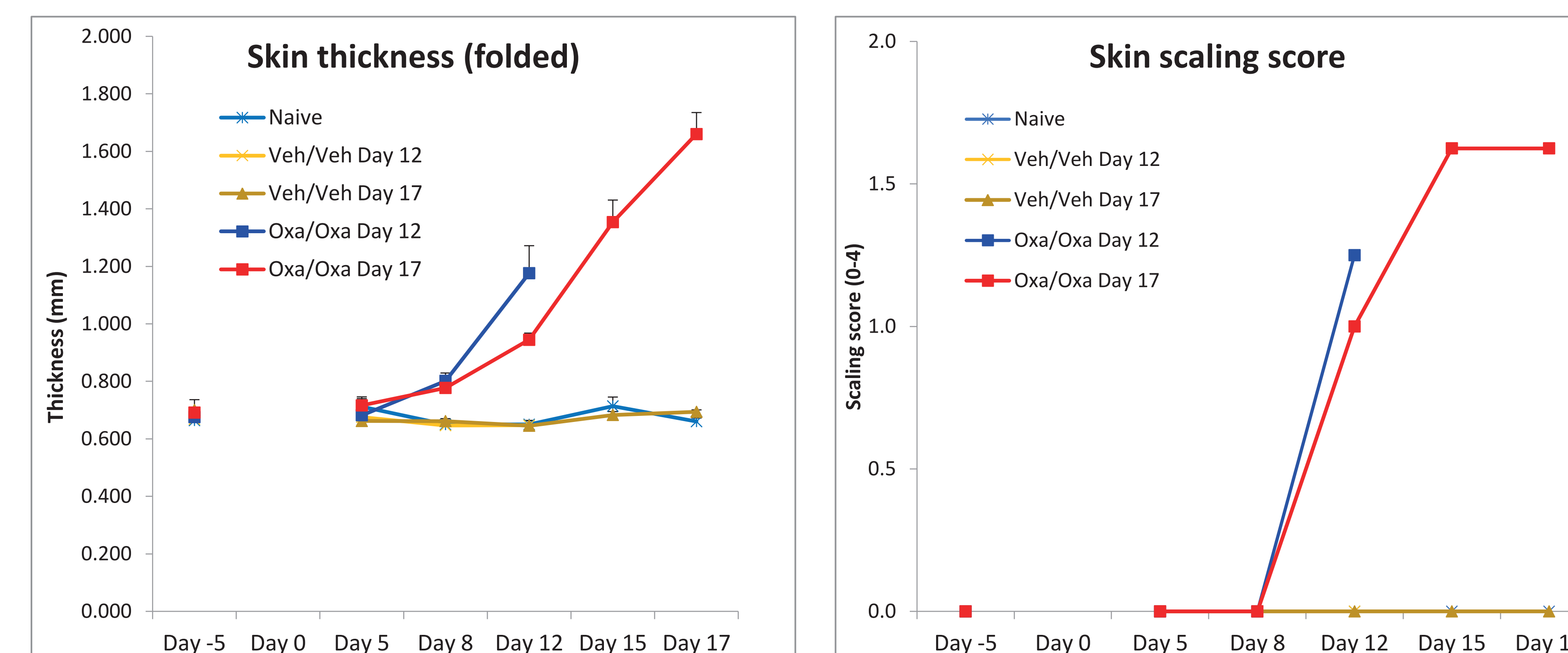


Figure 1: Two challenge applications of Oxazolone (Oxa) following sensitization induced milder clinical scores while four challenges of Oxa induced considerable increase in skin thickness and scaling (redness data are not shown) suggesting optimal induction of dermatitis.

## Histopathology and zymography

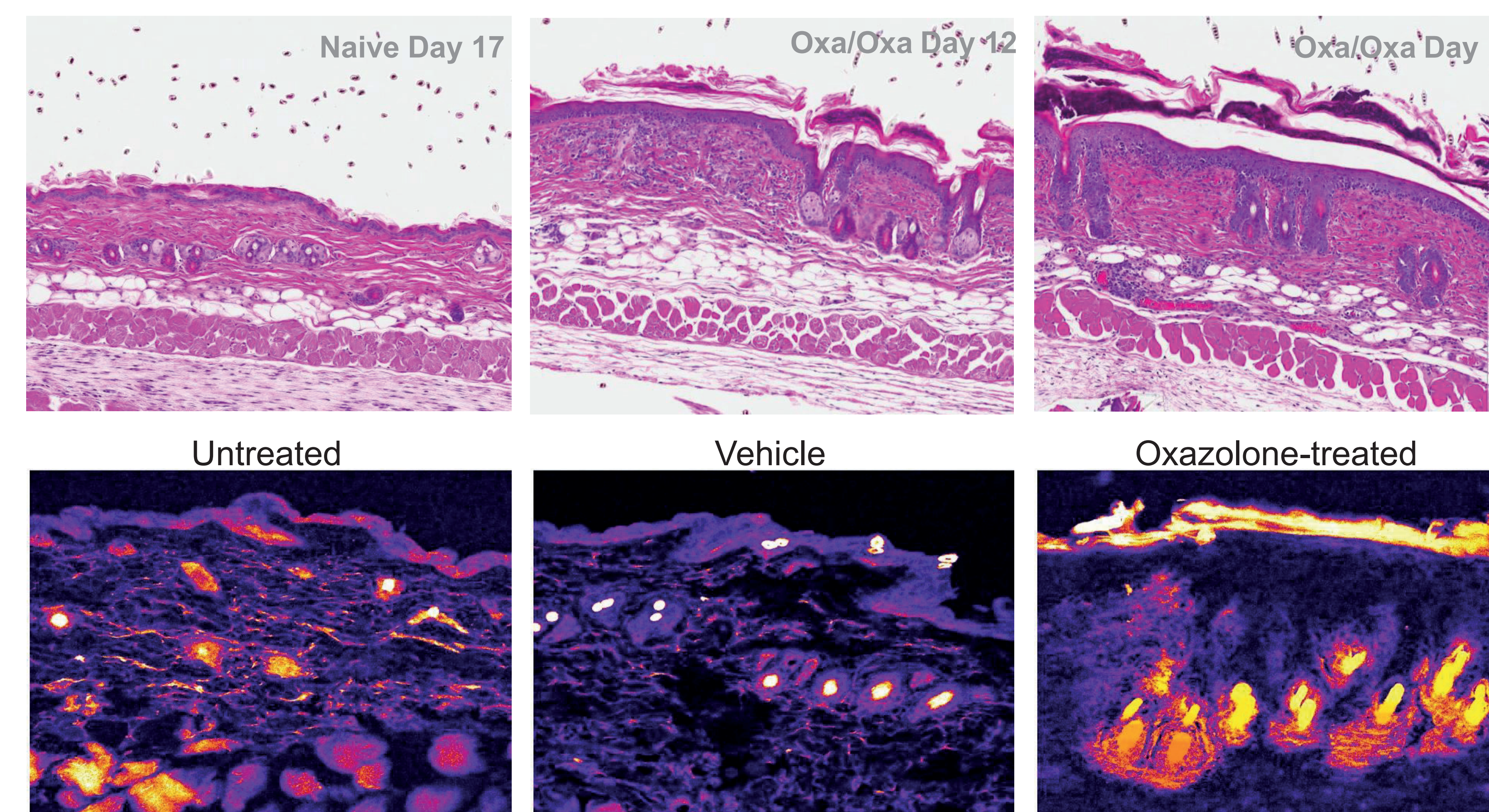


Figure 2: AD-like skin histopathological changes that include hyperkeratosis and crust in the stratum corneum, acanthosis or epidermal thickening and infiltration of inflammatory cells were observed both at Day 12 and Day 17 with slightly higher pathological scores at Day 17. In in-situ Zymography assay, increased tryptic activity was observed in the epidermal layer of Oxa/Oxa Day 17 mice compared with Veh/Veh-treated and Naive mice.

## Effects of test agents

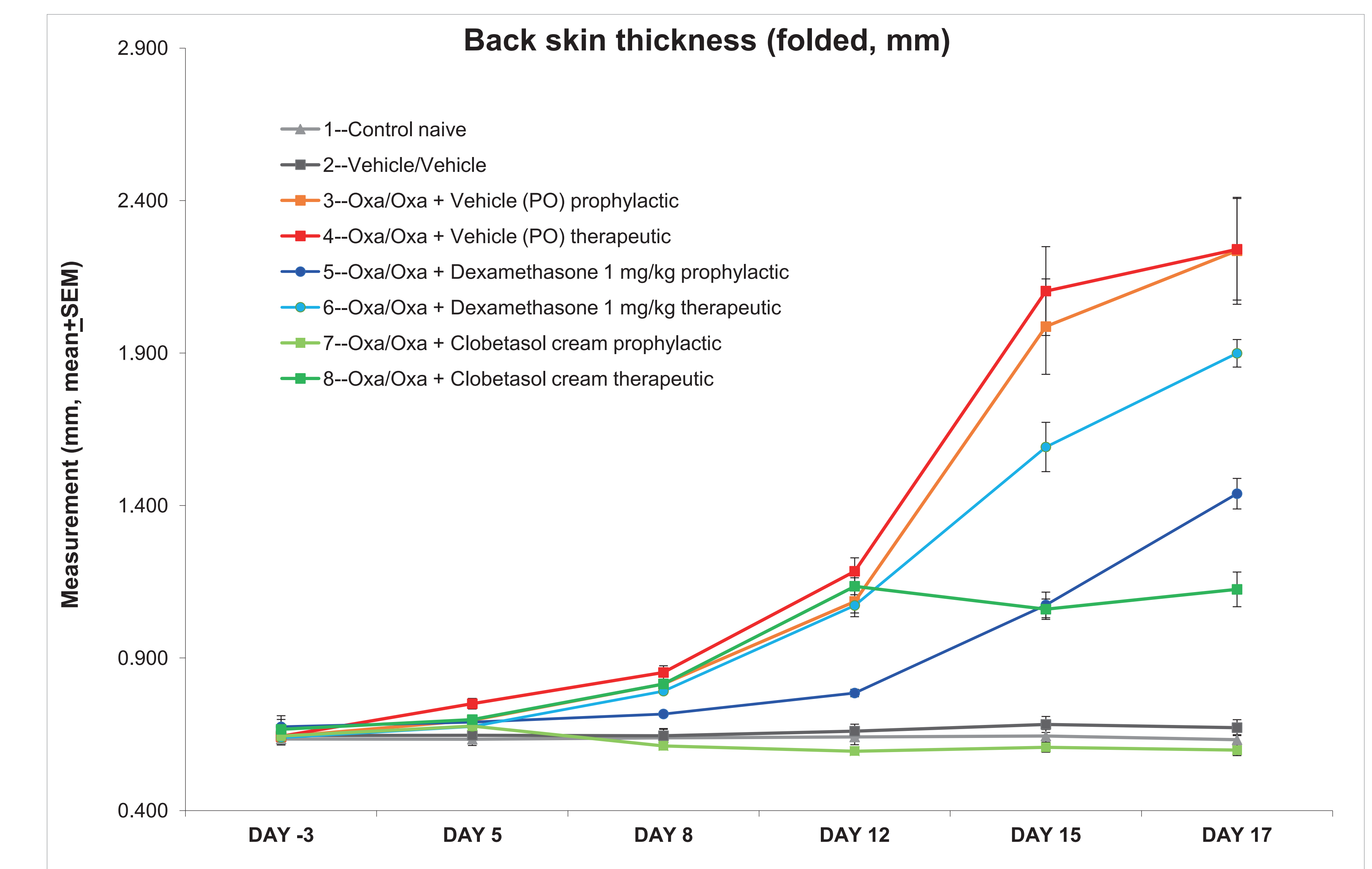


Figure 3: Effects of Dexamethasone (QD, oral gavage) and Clobetasol cream (QD, topical) were assessed on the Oxazolone-induced AD-like symptoms in mice in two different dosing protocol: prophylactic (Day 5 to Day 17) and Therapeutic (Day 12-Day 17). As shown above, prophylactic clobetasol cream completely blocked oxazolone-induced skin thickening and maintained at baseline level while therapeutic clobetasol arrested any further increase skin thickness after Day 12. Dexamethasone also inhibited AD-like skin thickening both in prophylactic and therapeutic dosing protocol although effect size was smaller than clobetasol. Similar effects were observed on skin redness and scales (data not shown).

## 4 Conclusion

- Significant AD-like skin symptoms could be induced in NC/Nga mice by repeated oxazolone challenges and optimal pathological changes were obtained with 4 Oxa challenges.
- Clinically used steroidal agents clobetasol cream and dexamethasone could attenuate Oxa-induced AD-like symptoms in NC/Nga mice.